

## The Tallest Man of Bangladesh Named Zinat Ali, A Case of Acromegaly with Hyperglycemia, Hypercholesterolemia and Major Depressive Disorder

Nusrat Shamima Nur\* and M. S. I. Mullick

Resident doctor of Child & Adolescent Psychiatry, Department of Psychiatry, Bangabandhu Sheikh Mujib Medical University, Dhaka, Bangladesh.

Professor of Child and Adolescent Psychiatry, Department of Psychiatry, Bangabandhu Sheikh Mujib Medical University, Dhaka, Bangladesh.

### \*Correspondence:

Nusrat Shamima Nur, Resident doctor of Child & Adolescent Psychiatry, Department of Psychiatry, Bangabandhu Sheikh Mujib Medical University, Dhaka, Bangladesh.

Received: 04 April 2019; Accepted: 28 April 2019

**Citation:** Nusrat Shamima Nur, M. S. I. Mullick. The Tallest Man of Bangladesh Named Zinat Ali, A Case of Acromegaly with Hyperglycemia, Hypercholesterolemia and Major Depressive Disorder. Int J Psychiatr Res. 2019; 2(2): 1-3.

### ABSTRACT

*Zinat Ali, the tallest man of Bangladesh as well as over the world who has recorded in Guinness Book of world record for his height. But he has some medical issues which make his living difficult day by day. Increasing height makes him more voracious food taker and he takes almost more than 1kg of rice daily. Moreover he has long fingers which are bending progressively. Even he has dissimilarities in length of legs, which are producing difficulties in walking. Nowadays he has started some symptoms of sad feeling which causes significant impairment in social, occupational and other areas of functioning. His condition has started to deteriorate in mentally, physically, financially and socially. His various problems of daily life are making him too irritated that his living is threatened now.*

### Keywords

Tallest man, Hepatomegaly, Hyperglycemia, Psychiatric illness.

### Introduction

Tallest man of Bangladesh named Zinat Ali has presented with some medical issues which are hampering his daily life. He is 7 feet and 2 inches tall man with dissimilarities in the height of legs. His fingers and toes are tall enough that it becomes bended. Enlargement of many parts of bones are significantly present in many areas of body. Moreover he has started to become sad in almost all the time in a day nearly every day. He also fulfills the criteria of Major Depressive disorder according to Diagnostic and Statistical Manual of Mental Disorder, 5th edition.

### Case Summary

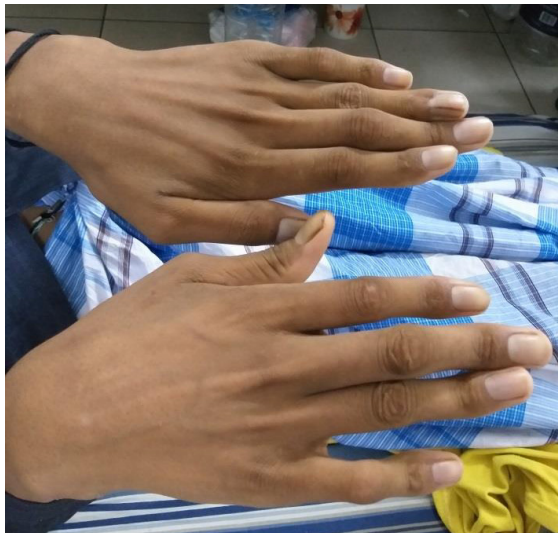On psychiatric evaluation of the tallest man shows that Zinat Ali, 19 years old, unmarried, muslim, farmer, right handed person, hailing from the rural area of Cox's Bazar, Chittagong, Bangladesh has presented with low self-esteem, lack of interest and pleasure, sleep disturbance for 6 months. According to the statement of the patient that he was completely well mentally 6 months back. Then

he develops low mood almost all the time in a day nearly every day associated with lack of interest and pleasure in all activities even at home, at work and at any work of entertainment. But previously he was too active in his daily activities of field of work. Moreover his deteriorating performance in work causes poor outcome of his financial condition. Nowadays he has to collect his financial supports from taking loans, by other's donation, by financial support from governments, by financial supports from non-government organization and so many, which makes him to feel more sad. He also has disturbance in sleep, which includes delayed onset of sleep, frequent awakening from sleep during the time of sleeping and early morning awakening. On asking he tells that nowadays it is difficult for him to take any decision, even he has confusion of taking the decision of operative treatment of his endocrine disorders.

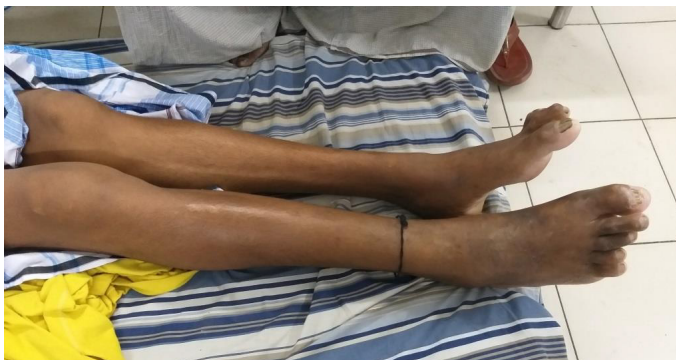In his past medical history he has diagnosed as a case of enlarged Sella Turcica or growth hormone producing tumor or Acromegaly. It is also associated with hepatomegaly, hyperglycemia, and mild hypercholesterolemia. In his past psychiatric history he has no other history of psychiatric illness previously. In his premorbid

personality he is sociable to friends, family, relatives and peer. His character is optimistic, mood is euthymic, and attitude is moral and religious. He passes his leisure period by playing games. Mental state examination revealed that he was a very tall man with imbalance in height of legs; he was well kempt, well combed and well dressed. His body built and nutritional state was below average. His facial expression was normal. Rapport was established and maintained. There were no abnormalities in posture and movement. There were no abnormalities in social behavior and motor behavior. Mood was depressed and affect was congruent. Flow, tone, rhythm, volume, quality of speech was normal. There was no oddity of speech. There were no thought abnormalities and no perceptual abnormalities. His consciousness was normal, attention was sustained. His immediate, recent and remote memory was intact. His judgment, intelligence and insight were intact.

Zinat Ali is a potential man of tallest height to utilize it for many world records. But his physical and mental condition is deteriorating day by day. He has diagnosed as a case of Acromegaly or enlarged Sella Turcica or growth hormone producing tumor. Here some investigation reports of Zinat Ali are given to see the medical condition of him. The investigations are done on 18th October, 2018.



**Figure 1:** Both hands of Zinat Ali show long fingers, joint swelling and bending fingers.



**Figure 2:** One leg is larger than another leg (right leg is larger) and joints are swollen, changes in the color of nails, asymmetry in finger

arrangement.

At first X-ray of both hands shows that enlargement of all phalanges are noted, metacarpo-phalangeal joint spaces are widely increased, sesamoid bones are noted in the metacarpo-phalangeal bones of the thumb. Soft tissue shadow is unremarkable. These features are suggesting acromegaly.

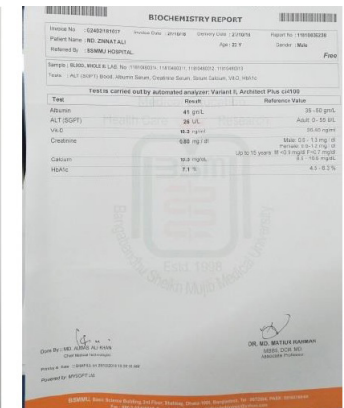
Then X-ray of both legs shows that both femoral and tibial condyles are widened and enlarged in size. Distal end of femur and proximal ends of tibia and fibula are enlarged. Osteophytes are found in the periarticular margin forming right knee joint. Joint space is widely increased. Tibial space is prominent. Epiphysis of proximal tibia has not completely fused yet. These features are suggestive of premature osteoarthritis of right knee joint.

X-ray of face and skulls shows that Sella turcica is enlarged in both antero-posterior and vertical diameter. No abnormal intracranial calcification is seen. No abnormal soft tissue lesion is seen. All visible paranasal air sinuses appear enlarge. Angle of mandible is widened. These features are suggestive of enlarged sella turcica.

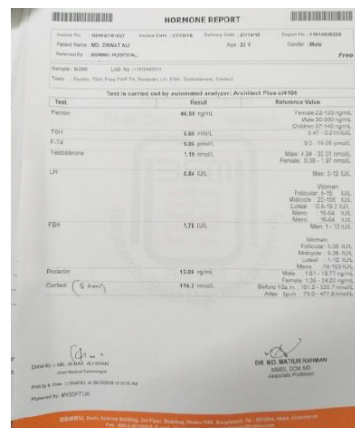
Some investigation reports with results are given:




**Figure: 3**



**Figure: 4**



**Figure: 5**



**Figure: 6**

- Investigation report of USG of whole abdomen done on 18th October, 2018 under imaging department of Bangabandhu Sheikh Mujib Medical University, Shahbag, Dhaka-1206,

Bangladesh.

- Investigation reports under biochemistry department of Bangabandhu Sheikh Mujib Medical University, Shahbag, Dhaka-1206, Bangladesh.

Albumin		41gm/L
ALT(SGPT)		26U/L
Vit-D		18.3ng/ml
Creatinine		0.80mg/dl
Calcium		10.3mg/dl
HbA1c		7.1%
Ferritin		46.59ng/ml
TSH		0.68 m IU/L
F-T4		9.06pmol/L
Testosterone		1.19 nmol/L
LH		0.84IU /L
FSH		1.78 IU/L
Prolactin		12.09 ng/ml
Cortisol		174.3nmol/L
Serum Lipid Profile	Total Cholesterol	220mg/dl
	HDL Cholesterol	28mg/dl
	LDL Cholesterol	89.8mg/dl
	Triglyceride	511mg/dl
Plasma Glucose	Fasting	8.3mmol/L
Serum Electrolyte	Sodium	135mmol/L
	Potassium	4.2mmol/L
	Chloride	103mmol/L
	T-CO2	25.7mmol/L

## Discussion

Patients with brain tumor are in risk of depression or depressive symptoms, but the estimated prevalence varies between studies. The aim of this case report is to get proper information of depression

and how it is related to sella turcica tumor. In a recently published case study, doctors describe how a woman with treatment-resistant depression was eventually diagnosed with a brain tumor (54-year-old woman who had been depressed for six months. She was experiencing apathy, difficulties making decisions, sleep disorders, suicidal thoughts, and problems with concentration and attention). 89% of adult brain tumor patients were examined in an ambulatory neuro-oncology clinic setting using a structured psychiatric interview which followed current DSM-IV diagnostic criteria for MDD. Both anatomic and physiological perturbations in the brain are likely involved in the associations between depression and brain tumors. Tumor treatments are also associated with depression.

## Conclusion

Zinat Ali, the tallest man of Bangladesh has gone through various troubles because of his growth hormone producing tumor. He also has the features of organomegaly such as hepatomegaly and others. This tallest man has many features of Acromegaly too.

## Acknowledgments

Zinat Ali, the tallest man of Bangladesh.

## References

- Jing Huang, Chao Zeng, Juxiong Xiao, et al. Association between depression and brain tumor: a systematic review and meta-analysis. *Oncotarget*. 2017; 8: 94932-94943.
- Jane Collingwood. Brain Tumors May Present as Depressive Symptoms. 8 Aug 2018.
- David K. Wellisch, Thomas A. Kaleita, Freeman D, et al. Predicting major depression in brain tumor patients *Psycho-oncology*. 2002; 11: 230-238.
- Scott Litofsky N, Andrew G, Resnick. relationships between depression and brain tumors. *Journal of Neuro-Oncology*. 2009; 94: 153-161.